

# Pseudoduplication of the optic nerve head

We present a case of pseudodoubling of the optic disc – a spectacular and rare clinical presentation. Of additional interest is that this case includes bilateral optic nerve pits.

In this report, we discuss the differentiation between true and pseudo-doubling of the optic disc and the issues involved in classification of and differentiation from the family of congenital optic nerve head anomalies and other clinical presentations resembling this condition.

## Case report

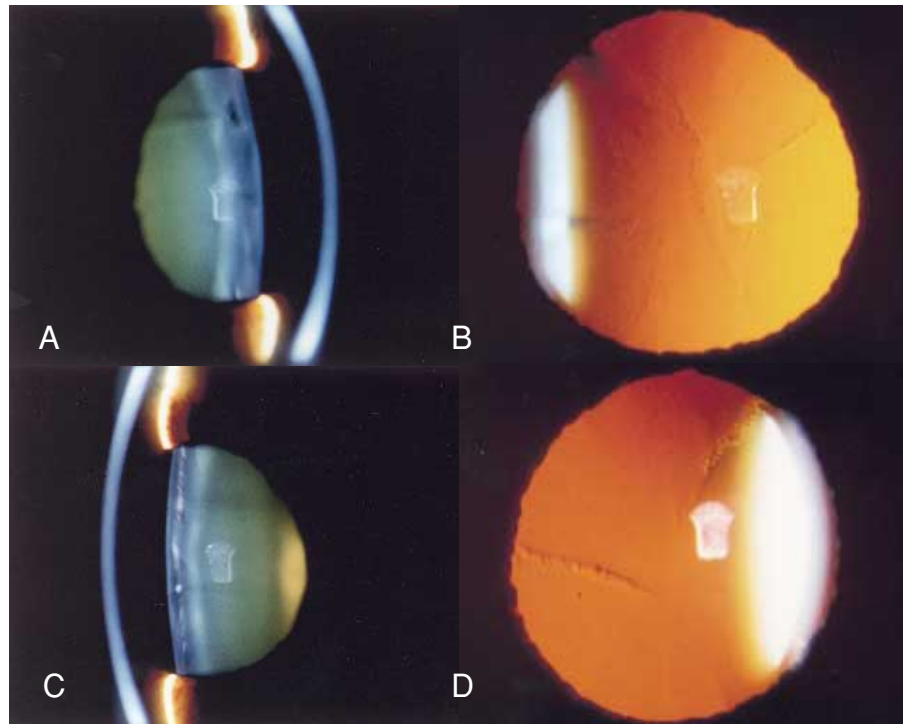
An 84-year-old woman presented with gradually decreasing vision in both eyes and difficulty in adjusting to dimly lit environments. She was aware that her left eye was unusual as her previous eyecare practitioner had photographed “the back of the eye” and presented her as a case study at a local ophthalmology meeting some 50 years earlier<sup>1</sup>. She was taking anti-hypertensive medication, but was in, otherwise, good health.

With her refraction of +3.50/-0.50 x 90 and +4.75/-0.75 x 100, she achieved visual acuities of 6/9.5 and 6/7.5, RE and LE, respectively. Addition of +2.50D enabled reading of N4 at near.

Pelli-Robson contrast sensitivity was mildly reduced to 1.40 and 1.10 (log CS), in the RE and LE, respectively, though contrast sensitivity under glare conditions (reduced by 0.30 and 0.15 log CS, respectively) was within age-matched normal limits<sup>2</sup>.

Color vision, assessed individually in both eyes with the Farnsworth D-15 panel test, was normal. Pupils were equal, round and reactive to light and accommodation.

Mild cataracts were present, as shown in **Figure 1**. This was graded with the LOCS III system proposed by Chylack et al<sup>3</sup>, in which nuclear opalescence and colour are rated on a decimal scale from 0 to 7 in steps of 0.1 and cortical and posterior subcapsular cataracts are rated on a decimal scale from 0 to 6: Nuclear opalescence (NO) 2.8 Nuclear colour (NC) 2.6 Cortical (C) 3.2 Posterior (P) 0.5, RE; NO 3.0 NC 2.9 C 3.0 P 0.5, LE. Mild changes were also observed in the retinal pigment epithelium of both maculae. The right optic disc appeared normal, except for a temporally located optic



**Figure 1:** a. Slit view of the right lens showing minimal cataractous change. b. Retro-illumination of the right lens. c. Slit view of the left lens showing minimal cataractous change. d. Retro-illumination of the left lens.

nerve pit (**Figure 2**). The left optic disc appeared to be duplicated inferiorly (**Figure 3**).

An optic nerve pit was also present in the true optic papilla. A cilioretinal artery was observed to exit from the optic nerve pit to subserve the inferior temporal retina. All the vessels subserving the superior vessel arcades exited the true optic disc. In addition, three vessels subserving the inferior vessel arcades were observed exiting from the inferior lesion. Visual fields were normal in the right eye but there was a paracentral arcuate scotoma in the left (**Figure 4**). Intraocular tensions were 15 mmHg BE. Since the optic pits were located temporally instead of superiorly or inferiorly, they were probably congenital rather than acquired, as from glaucoma.

$\beta$ -scan ultrasonography of the left eye and orbit was conducted and this demonstrated the presence of only one optic nerve (**Figure 5**), establishing the diagnosis of pseudodoubling of the left optic disc.

Based on the symptoms of adaptational difficulties, improvement with refraction, normal glare loss and contrast sensitivity, the patient's difficulties were attributed to refractive change, mild age-related macular degeneration and early cataracts.

## Discussion

Pseudodoubling of the optic disc is an extremely rare condition. The authors are only aware of two previous reports<sup>4,5</sup>. In both cases the lesion, resembling a second optic nerve head, was located inferior to the disc within the region of the optic fissure, with apparent cupping and surrounding chorioretinal atrophy. The lesions reported in these three cases all resemble optic papillae in terms of size, shape and vascularisation. In two cases, the timing of vessel filling during fluorescein angiography suggested the vessels were continuous with the central retinal vessels<sup>5,4</sup>.

The other eye may be normal<sup>4</sup>, although in this case the fellow eye was also affected by a congenital optic disc anomaly. Similarly, visual acuity may be normal or impaired<sup>4</sup>. Visual field defects have been reported and probably correspond to congenital nerve fibre bundle absence<sup>4</sup>. The paracentral visual field defect in this case is typical of that seen with an optic nerve pit<sup>6</sup>, and is likely to reflect this finding rather than the presence of the disciform lesion.

## Differential diagnosis

The circumscribed, disk-like appearance of this lesion, in combination with the presence of

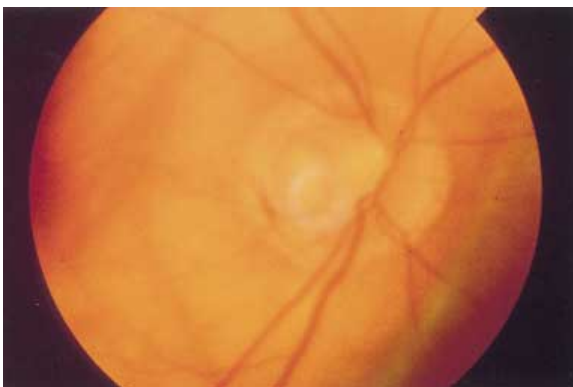
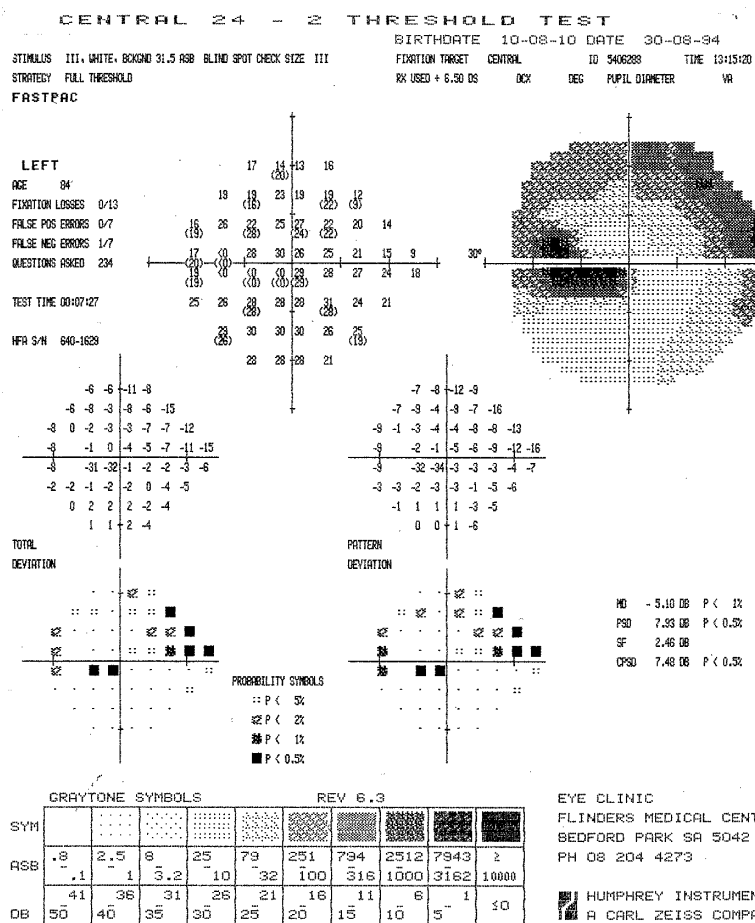


Figure 3: The right optic disc with a large optic nerve pit surrounded by nerve fibres in the temporal sector.

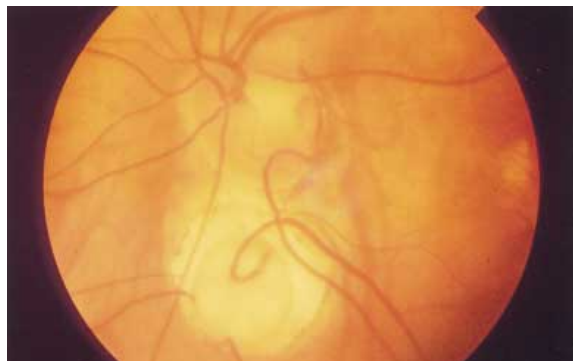

Figure 4: Apparent duplication of the left optic disc. The true optic disc is superior to the lesions resembling a second disc and contains an optic nerve pit abutting the temporal margin of the disc. The majority of vessels exit the true optic disc, but three major vessels subserving the inferior arcades exit the inferior lesion. A cilioretinal artery exits from the optic nerve pit in the true optic disc. Some RPE pigment changes are visible at the macula on the right of the picture.

Figure 2: Humphrey 24-2 visual field of the left eye showing a paracentral arcuate scotoma.

blood vessels and proximity to the true optic nerve head makes it easily distinguishable from other retinal lesions such as myopic (and other retinal) staphyloma, previous infection from toxoplasmosis or those resulting from trauma. The primary differential diagnosis of pseudodoubling of the optic disc, therefore, is a true second optic disc, and can be achieved by imaging the orbit with MRI<sup>4</sup>, CT or more cost-effectively with  $\beta$ -scan ultrasonography. Three cases of true optic disc doubling have been reported<sup>7-9</sup>. Brink and Larsen (1977) suggested that a double blind spot is also suggestive of true optic disc doubling<sup>7</sup>. Fluorescein angiography may also be helpful as a true optic disc will show late hyperfluorescence whereas a disciform lesion will not<sup>5</sup>.

**Origin and classification of congenital anomalies of the optic nerve head**

Although once considered to be part of a spectrum of disease, congenital anomalies of the optic disc such as optic disc coloboma, morning glory disc anomaly, peripapillary

staphyloma, optic nerve pits and optic nerve head dysplasia are now thought to be distinct clinical entities<sup>10-12</sup>.

Optic nerve head and chorioretinal colobomata represent a primary structural dysgenesis involving the proximal embryonic fissure, and may occur in conjunction<sup>13</sup>. The term optic disc coloboma should only be used for those cases with an inferiorly decentred, white, bowl-shaped excavation of the optic nerve head without significant peripapillary pigmentary changes<sup>13</sup>.

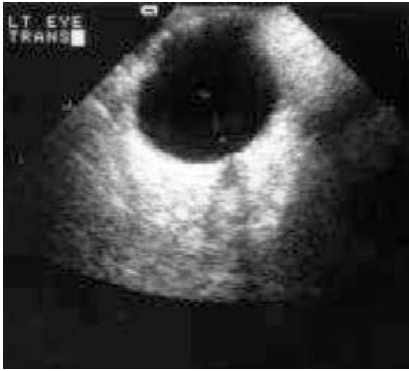
Optic nerve pits, once considered to be part of a spectrum of disease with optic disc coloboma, are now thought to be fundamentally distinct in their pathogenesis<sup>13</sup>. However, numerous cases of optic nerve pits occurring in the presence of true optic disc colobomata have been reported<sup>6,14,15</sup>, suggesting that the presence of an optic disc coloboma encourages optic nerve pit formation.

Interestingly, colobomata manifest bilaterally as often as unilaterally (and may be asymmetrical)<sup>16,15</sup>, whereas optic nerve pits are bilateral in only 15% of cases<sup>16</sup>. Cases of a

coloboma in one eye and an optic nerve pit in the other have been reported<sup>15</sup>. Interestingly, optic nerve pits are associated with serous macular detachment, though the nature of the serous fluid, be it cerebrospinal, orbital, vascular or vitreous in origin, is still debated<sup>13,17</sup>.

Morning glory optic disc anomaly, peripapillary staphyloma, megalopapilla and congenital tilted disc syndrome are all separate clinical entities<sup>10,13</sup>. Markedly deformed optic discs that cannot be otherwise classified are generally referred to as optic nerve head dysplasia. In addition, endocrinologic disorders such as growth hormone deficiency have been associated with other congenital optic nerve anomalies, such as optic nerve hypoplasia<sup>13</sup>. In this case, however, the patient suffered no systemic disease, nor are the authors aware of any direct association between pseudo-doubling of the optic disc and endocrinologic dysfunction.

The authors propose that pseudodoubling of the optic disc is a chorioretinal coloboma, with optic disc involvement. This is supported by the observation that the disciform lesion is



**Figure 5:**  
 β-scan ultrasonograph showing the presence of only one optic nerve exiting from the left eye. There is no oblique entry, posterior globe protrusion or evidence of any other abnormality.

located inferior to the disc, in the region of the embryonic fissure. The chorioretinal coloboma, coincidentally, is of similar shape and size to the optic papilla, and there is sufficient optic nerve involvement to create vascular communication between the disciform lesion and the central retinal vessels. The existence of bilateral optic nerve pits in this case of pseudodoubling of the optic nerve is consistent with the proposal that the disciform lesion is, indeed, a coloboma. As such, there may be an increase in the risk of rhegmatogenous retinal detachment associated with this type of (chorio-retinal colobomatous) lesion<sup>17</sup>.

### Acknowledgments

The authors wish to thank Angela Chappell and Wendy Laffer of the Department of Ophthalmology, Flinders Medical Centre for photography and editorial assistance respectively.

### About the authors

Konrad Pesudovs is a ?? in the Department of Ophthalmology, Flinders Medical Centre and Flinders University of South Australia, Bedford Park, South Australia, 5042, Australia and ?? Department of Optometry, University of Bradford, Bradford, West Yorkshire, BD7 1DP, UK

Harrison S. Weisinger is at the Department of Food Science, Royal Melbourne Institute of Technology University, Melbourne, Victoria, 3000, Australia

### Correspondence

Correspondence should be sent to Konrad Pesudovs, Department of Optometry, University of Bradford, Bradford, West Yorkshire, BD7 1DP, UK.  
 Tel.: 01274 234642; fax: 01274 235570  
 e-mail: konradp@bettanet.net.au

### References

1. Slade, J.H. Optic papilla doubling. South Australian Branch Meeting of The Royal Australian College of Ophthalmologists. Adelaide, South Australia: 1949.
2. Pesudovs, K. Coster, D. Visual function in cataract patients with a mean visual acuity of 6/9. *Aust NZ J Ophthalmol* 1996;24:5-9.
3. Chylack, L.T. Jr. Wolfe, J.K. Singer, D.M. Leske, C. Bullimore, M.A. Bailey, I.L. Friend, J. et al. The lens opacities classification system III. *Arch Ophthalmol* 1993;111:831-6.
4. Barboni, P. Deluigi, M. DeBonis, C. Monetti, G. Savini, G. Zanini, M. Pseudodoubling of the optic disc. *Arch Ophthalmol* 1998;116:1400-1.
5. Brink, J.K. Larson, F.E. Pseudodoubling of the optic disc: a fluorescein angiographic study of a case with coloboma. *Acta Ophthalmol* 1977;55:862-70.
6. Brown, G.C. Shields, J.A. Goldberg RE. Congenital pits of the optic nerve head II. Clinical studies in humans. *Ophthalmol* 1980;87:51-65.
7. Lamba, P.A. Doubling of the papilla. *Acta Ophthalmol* 1969;47:4-9.
8. Elbrechtz, H.C. Über eine doppelte Papille im Auge. *Klin Monatsbl Augenheilkd* 1975;166:389-91.
9. Junge, J. Über eine doppelte Papille im Augenkolobom. *Klin Monatsbl Augenheilkd* 1978;172:748-50.
10. Pollock, S. The morning glory disc anomaly: Contractile movements, classification and embryogenesis. *Doc Ophthalmol* 1987;65:439-60.
11. Traboulsi, E.I. O'Neill, J.F. The spectrum in the morphology of the so-called "morning glory disc anomaly" *J Pediatr Ophthalmol Strabismus* 1988;25:93-8.
12. Brodsky, M.C. Morning glory disc anomaly or optic disc coloboma? *Arch Ophthalmol* 1994;112:153.
13. Brodsky, M.C. Congenital optic disc anomalies. *Surv Ophthalmol* 1994;39:89-112.
14. Goldberg, R.E. Optic nerve pit and associated coloboma with serous detachment. *Arch Ophthalmol* 1974;91:160-1.
15. Gündüz, K. Gündüz, K. Okudan, S. Özbayrak, H. An unusual finding in a patient with optic nerve pit syndrome. *Doc Ophthalmol* 1993;84:171-8.
16. Brown, G.C. Augsburger, J.J. Congenital pits of the optic nerve head and colobomas. *Can J Ophthalmol* 1980;15:144-146.
17. Alexander, L.J. Congenital and acquired anomalies of the optic nerve head. In: *Primary Care of the Posterior Segment*. East Norwalk: Appleton and Lange, 1989: 1-68.

