

Sarcoidosis: case report and review

Clin Exp Optom 2006; 89: 6: 361–367

DOI:10.1111/j.1444-0938.2006.00082.x

Harrison S Weisinger * MScOptom MBBS
PhD

Daniel Steinfors * BMedSci MBBS

Adam D Zimmet † BMedSci MBBS

Anthony JH Hall § MD FRANZCO FRACS

Konrad Pesudovs || BScOptom PhD

PGDipAdvClinOptom FVCO FAAO

FCLSA

* Department of Respiratory Medicine and

† Department of Cardiothoracic Surgery,
St Vincent's Hospital, Victoria, Australia

§ Eye Surgery Associates, East Melbourne,
Victoria, Australia

|| NH&MRC Centre for Clinical Eye
Research, Department of Ophthalmology,
Flinders Medical Centre, Flinders
University, Bedford Park, SA, Australia

E-mail: weisinger@mac.com

Sarcoidosis is a granulomatous disorder of uncertain aetiology that can affect almost any organ. Anterior uveitis is a feature of the condition in about 30 per cent of those affected. We describe a patient with sarcoidosis presenting with anterior uveitis and describe a diagnostic approach.

Sarcoidosis is a condition that must be considered in patients presenting with symptomatic uveitis, as the underlying disease is serious and usually treatable. The diagnosis of sarcoidosis is aided by an understanding of the pattern of organ involvement and may ultimately require tissue confirmation through biopsy of granulomata, including those found in the ocular adnexa.

Submitted: 12 March 2006

Revised: 4 June 2006

Accepted for publication: 10 June 2006

Key words: anterior uveitis, granuloma, lung disease, posterior uveitis, sarcoidosis, vitritis

Sarcoidosis is a chronic multisystem inflammatory condition, primarily affecting young adults aged between 20 and 40 years.^{1–3} The hallmark of the disease is non-necrotising granulomata in affected organs, which most commonly include the lung, eyes and skin. Importantly, sarcoid-related uveitis represents some seven per

cent of all uveitis presenting to eye specialists.⁴

CASE REPORT

A 36-year-old Ethiopian woman, who immigrated to Australia in 1999, presented to St Vincent's Hospital with a six-

month history of lethargy and intermittent severe left upper quadrant and epigastric abdominal pain. She reported recent weight loss of about 15 kg. At the time of presentation, she stated that she had already received several months of treatment for anterior uveitis in the left eye only and that the vision remained

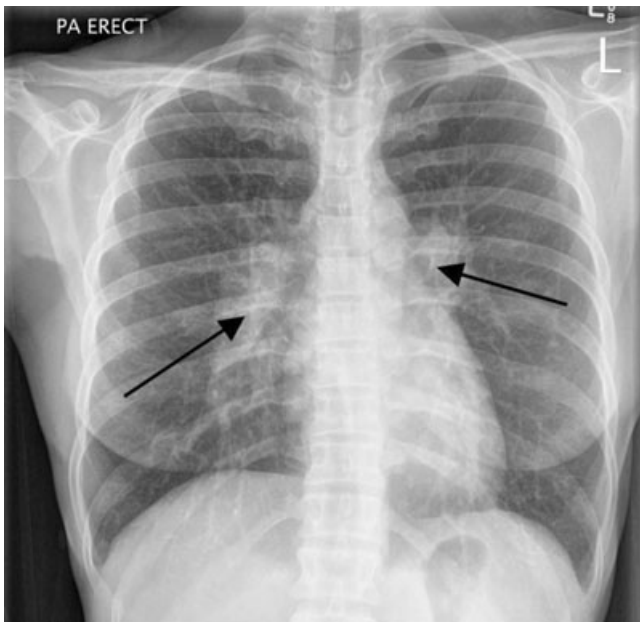


Figure 1. CXR demonstrating bilateral hilar lymphadenopathy (arrows)

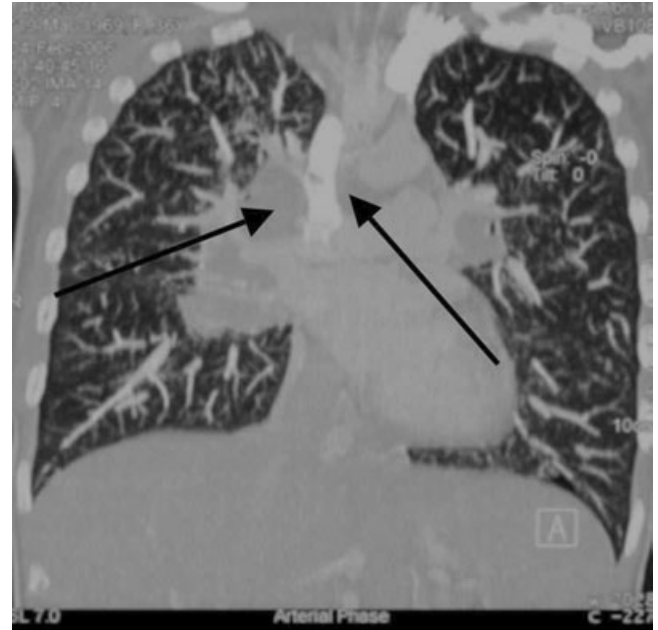

Figure 2. Sagittal CT chest scan demonstrating tracheo-bronchial lymphadenopathy (arrows)

significantly reduced. Her last recorded visual acuities (VA) were 6/6 and 6/9 in the right and left eyes, respectively. She was otherwise well. There was no history of fever or night sweats and no respiratory symptoms. Her past medical history included six months of single agent therapy (isoniazid) for latent tuberculosis in 2000.

On examination, she was moderately cachectic (appeared to have lost weight and muscle mass due to disease). The vital signs were unremarkable, the respiratory examination was normal and she was not jaundiced. Her abdomen was soft and non-tender, though palpation revealed moderate hepatosplenomegaly. At presentation, there was no identified palpable lymphadenopathy. The eyes were not examined at this stage.

A chest x-ray (CXR) demonstrated bulky bilateral hilar lymphadenopathy (BHL) (Figure 1). The lung fields were otherwise clear. Follow-up CT scan of the thorax revealed the presence of further lymphadenopathy in the right tracheo-

bronchial angle and sub-carinal locations. This is well appreciated in sagittal reconstruction (Figure 2). There was no interstitial involvement. Abdominal ultrasound demonstrated normal bile duct diameter, thus ruling out the presence of gall-stone disease as an explanation for her abdominal pain. CT scan of the abdomen revealed pathological para-aortic lymph nodes (Figure 3).

Given the patient's history and radiological findings, the most likely differential diagnoses considered at this time included lymphoma, tuberculosis and sarcoidosis. Full blood examination, serum electrolytes, serum and urinary calcium and quantiferon (interferon response to tuberculous antigens) were all normal. Liver function tests revealed a mildly cholestatic picture, with no elevation of ALT or bilirubin. Serum amylase and lipase levels were normal. β -2-microglobulin and LDH levels were slightly elevated, though not to the level often found in lymphoma, leukaemia or myeloma. HBV, HCV, HIV serology was negative. Serum

ANA, ANCA, rheumatoid factor and ENA levels were normal.

The patient underwent fiberoptic bronchoscopy that did not demonstrate any endobronchial involvement. Bronchial washings were negative for malignancy and lymphocytosis.

One week after presentation, the patient developed palpable lymphadenopathy in the right supra-clavicular fossa, enabling a minimally invasive biopsy. At biopsy, a large golden yellow node was excised. Histological examination revealed non-necrotising granulomata consistent with sarcoidosis. She was commenced on high dose oral prednisolone (60 mg/d).

Two days after diagnosis and the commencement of treatment, the patient complained of new sudden onset visual disturbance in the right eye. VA in the right eye (6/6 at presentation) had declined to 6/12 (6/7.5 through a pinhole). VA in the left eye was 6/9 with no improvement through a pinhole. Both pupils were fixed and dilated. Eye movements were normal.

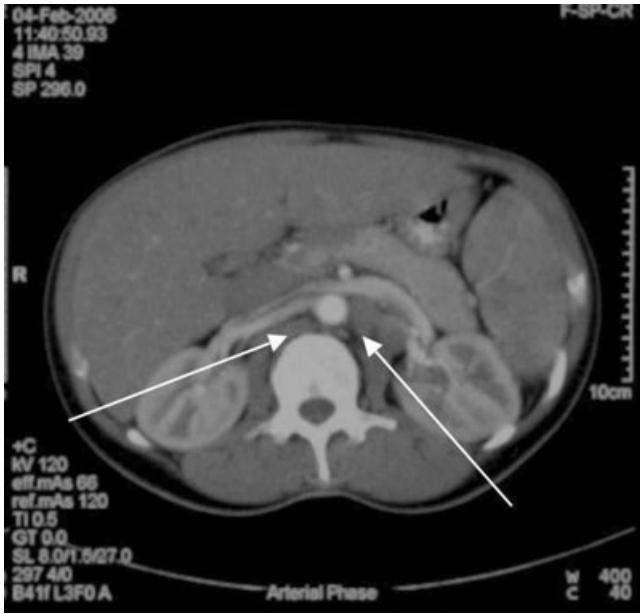


Figure 3. CT Abdomen demonstrating para-aortic lymphadenopathy (arrows)

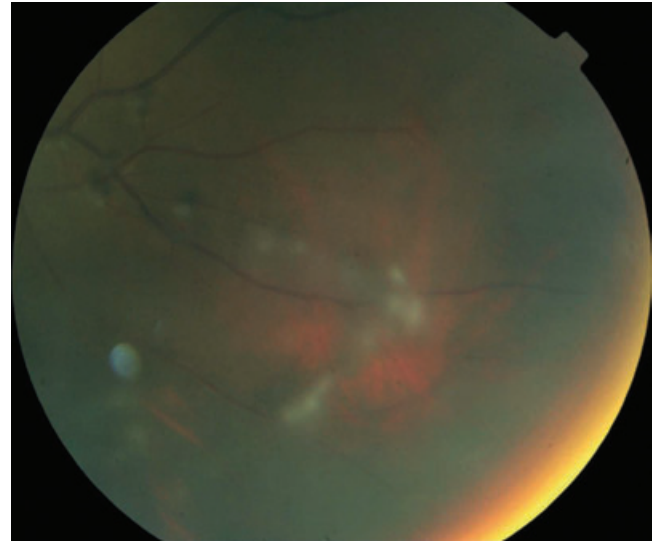


Figure 4. 'String-of-pearls' vitritis in sarcoid intermediate uveitis

Slitlamp examination revealed bilateral posterior synechiae. An iris nodule was present in the right eye. The anterior chambers contained low-grade flare with cells and keratic precipitates were observed in the left eye only. The angles were open and intra-ocular pressures were normal.

Internal examination revealed vitritis in the right eye in the classical 'string of pearls' distribution (Figure 4). There was no retinal involvement and no frank macular oedema. She was commenced on Prednefrin forte and homatropine and continued oral prednisolone.

She was reviewed two weeks later, at which time she denied symptoms of abdominal pains or anorexia. Her visual acuity had returned to 6/7.5 in the right eye with some resolution of her anterior uveitis. Further follow-up, one month after discharge, revealed improvement in VA to 6/6 and 6/7.5, with further resolution of her intra-ocular inflammation. At this time, her intra-ocular pressures had risen to 22 and 26 mmHg and these were treated with aqueous suppressants. At the time of acceptance of this article, the

patient continues to be monitored every three months.

DISCUSSION

The prevalence of sarcoidosis has been estimated at 15 per 100,000 population and, in the USA, is three times more prevalent in blacks than whites.^{5,6} Its aetiology is unknown, though a range of factors including tuberculous infection, beryllium exposure (though rare now) and cold climate have been implicated in the pathogenesis of the condition.² An immuno-genetic predisposition has been demonstrated through family studies⁷ and more recent research has found that particular alleles within the major histocompatibility complex (MHC) confer susceptibility to the disease.^{5,8,9}

Pathophysiology

The lung is the most commonly affected organ in sarcoidosis and 90 per cent of cases have changes evident on CXR.¹⁰ Approximately 50 per cent of those affected are asymptomatic at the time of

diagnosis, having been detected as incidental findings on routine CXR.^{8,11} When symptomatic, the predominant pulmonary features are of cough, shortness of breath and chest pain. Physical examination of the chest is normal in most cases.

The classification of pulmonary sarcoidosis is performed radiographically^{6,10} according to the presence of:

- Stage I hilar and mediastinal lymphadenopathy
- Stage II hilar lymphadenopathy with lung infiltrates
- Stage III interstitial infiltrates with shrinking hilar nodes
- Stage IV advanced interstitial fibrosis.

The radiographic staging of sarcoidosis correlates well with prognosis^{11,12} and is used to guide surveillance intervals.¹¹

Non-specific systemic features of sarcoidosis are often present, mimicking those of malignancy and chronic infection. These include anorexia and cachexia, fever, fatigue and weakness. Indeed, non-specific constitutional symptoms may be the only features of sarcoidosis in older patients presenting for the first time.

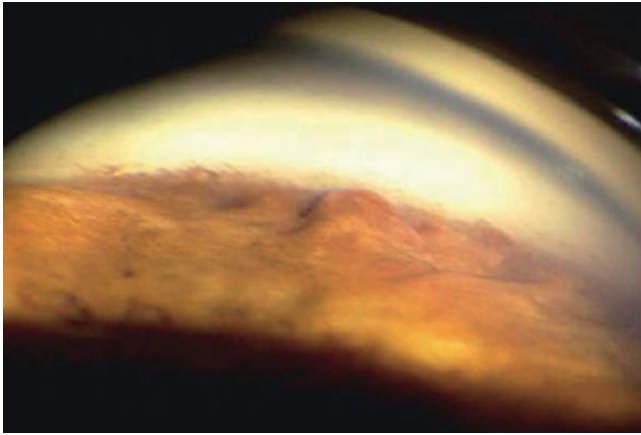


Figure 5. Iris nodules in sarcoid anterior uveitis (from case photograph library, Department of Ophthalmology, FMC)

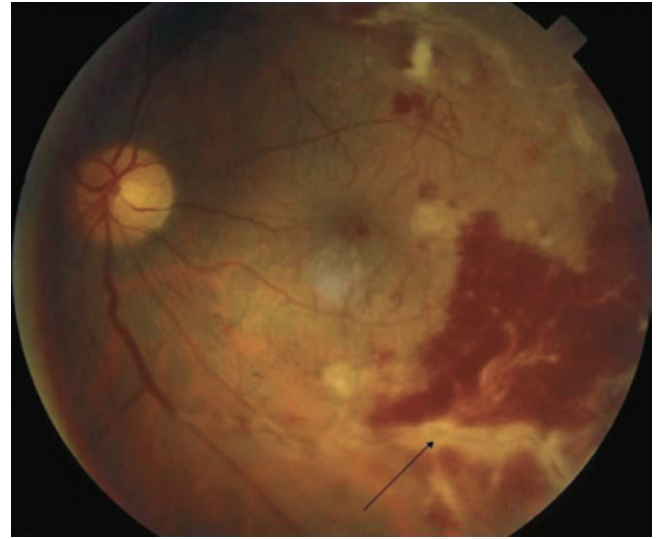

Figure 6. 'Candle-wax dripping' exudative vasculitis, haemorrhage and cystoid macular oedema in sarcoid eye disease (from case photograph library, Department of Ophthalmology, FMC)

Extra-pulmonary sarcoidosis can affect a range of organs and homeostatic functions. A brief list is provided in Table 1.

Ocular involvement in sarcoidosis

Ocular involvement in sarcoidosis usually presents as decreased VA with haze, floaters, variable pain, photophobia and lacrimation but sarcoidosis can affect the eyes in many ways. We will consider the pathogenesis of such presentations in three sections: anterior segment, posterior segment and the adnexa / extra-ocular structures.

ANTERIOR SEGMENT

Most commonly, sarcoidosis presents in the anterior segment as a painful unilateral granulomatous uveitis with cells, flare and mutton-fat keratic precipitates.^{4,13} An alternative presentation is that of Lofgren's syndrome, which describes the condition of bilateral chronic smouldering low-grade granulomatous ocular inflammation in addition to BHL, arthritis, erythema nodosum and constitutional symptoms.¹⁴ Granulomatous iris nodules of the stroma ('Busacca nodules')

Ocular involvement (covered in text)
Parotid gland enlargement
Cranial nerve palsy
Granulomatous basal meningitis
Cardiac arrhythmia / heart failure / sudden cardiac death
Granulomatous liver disease
Bone cysts
Skin plaques
Lupus pernio (purple granulomatous indurated lesion of the skin)
Erythema nodosum
Hypercalciuria and renal stones
Hypothyroidism
Infertility

Table 1. Extra-pulmonary involvement in sarcoidosis

(Figure 5) and of the pupillary margin ('Koeppe nodules'), anterior synechiae, posterior synechiae and ocular hypertension are other frequent findings.^{13,15}

Less commonly, sarcoidosis manifests as conjunctival granulomata and conjunctivitis, keratitis sicca (particularly if lacrimal

glands are involved), episcleritis, scleritis and interstitial keratitis. Chronic intra-ocular inflammation in sarcoidosis can result in cataract formation.^{4,6,13,15}

POSTERIOR SEGMENT

Approximately one-third of patients with ocular sarcoidosis have posterior segment involvement. It often takes the form of intermediate uveitis¹⁶ (inflammation of the vitreous and peripheral retina) in which white snowball opacities within the vitreous form the classical 'string of pearls' (Figure 4) in association with retinal vasculitis and exudates ('candle-wax dripping') and phlebitis ('venous sheathing'). Peripheral neovascularisation with or without haemorrhage is not uncommon.¹³ Figure 6 demonstrates a case of severe sarcoid-related posterior uveitis with cystoid macular oedema, haemorrhage and candle-wax dripping.

Sarcoidosis can also result in sight-threatening cystoid macular oedema, multifocal choroiditis and granuloma (Figure 7), which carries a poor visual prognosis,¹⁷ inflammatory optic nerve swelling or frank optic nerve granulomata.

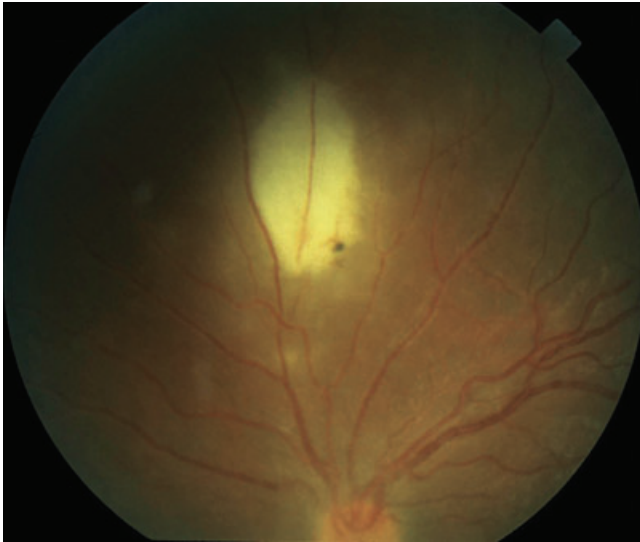

Figure 7. Choroidal granuloma in sarcoid eye disease (from case photograph library, Department of Ophthalmology, FMC)

OCULAR ADNEXA/EXTRA-OCULAR STRUCTURES

As a disease entity, sarcoidosis spares almost no part of the eye and adnexa. Asymptomatic swelling of the upper lid occurs as a consequence of lacrimal gland involvement.¹⁸ Proptosis may indicate granulomatous extra-ocular muscle involvement¹⁹ or involvement of the globe itself.

Diagnosis

Sarcoidosis should be considered in any young patient presenting with anterior uveitis. The differential diagnoses for anterior uveitis in young people include:

- HLA B27-related disease, the so-called 'sero-negative spondyloarthropathies' (that is, ankylosing spondylitis, Reiter's syndrome, inflammatory bowel disease, psoriatic arthritis)
- systemic inflammatory diseases (that is, sarcoidosis, Behçet's disease)

- systemic infections such as syphilis (and atypical infections, for example, TB, cryptococcus, fungi)
- neoplasia.

As its features are shared with many conditions and because of its often non-specific presentation, the diagnosis of sarcoidosis can be difficult and is often delayed.²⁰ In general, patients with dermatological or ocular involvement (except in cases of isolated neuro-ophthalmological disease²¹) are diagnosed early, whereas those without localising symptoms and those with pulmonary involvement only are diagnosed relatively late.²⁰ Patients with posterior or intermediate uveitis, such as described in this case report, are less likely to have HLA B27-related disease, hence other diagnoses should be considered.

The elements of a diagnosis of sarcoidosis are:

- clinical and radiographic findings consistent with the condition

Full blood examination
Anaemia
Leukopenia, eosinophilia, thrombocytopenia
Erythrocyte sedimentation rate elevated
Serum biochemistry / serology
Hypercalcaemia (and hypercalciuria)
Hypergammaglobulinaemia
Alkaline phosphatase elevated
Angiotensin converting enzyme elevated
Pulmonary function tests
Restrictive lung disease pattern
Gas diffusion decreased
Broncho-alveolar lavage (BAL) and trans-bronchial biopsy
Lymphocytosis
CD4:CD8 ratio > 4
Confirmatory biopsy
Gallium-67 lung scan (not routinely used)
Increased uptake corresponding to inflammatory alveolitis
Other imaging
There is currently no recognised role for PET or MRI scanning in the diagnosis and staging of sarcoidosis

Table 2. Additional investigations for sarcoidosis

- histological evidence of non-necrotising granulomata
- the exclusion of other conditions with similar features (for example, tuberculosis and histoplasmosis).^{2,6,20}

In addition to CXR and CT chest (with high resolution cuts), several laboratory tests can add weight to the likelihood of the diagnosis. These are listed in Table 2.

The best confirmatory diagnostic test is histopathological analysis of biopsied tissue. Any accessible lesion can be considered, including granulomata of the lid and orbit, but more commonly lymph nodes, subcutaneous nodules and cutaneous lesions. If there are no easily accessible lesions, trans-bronchial or endoscopic ultrasound-guided fine needle biopsy may be undertaken to avoid a surgical approach.⁶ In many patients with mild disease and a typical CXR, histological confirmation is considered unnecessary.

Management

The natural history of pulmonary sarcoidosis is varied and therefore, unpredictable with a proportion of patients undergoing spontaneous resolution and others progressing to advanced lung fibrosis and death⁸ (from respiratory failure in one to five per cent¹¹). Chronic progressive disease occurs in about one-third of cases, featuring a relapsing-remitting course in which spontaneous resolution is frequent.¹² As a rule, nearly all cases of Stage I disease but almost none of those with Stage IV disease resolve within two years.¹¹ Adverse prognostic features include cardiac involvement, chronic hypercalcaemia, chronic uveitis, pulmonary fibrosis and neurological disease.¹⁰⁻¹²

THERAPY FOR SYSTEMIC DISEASE

Systemic corticosteroids are the mainstay of treatment for sarcoidosis. A recent Cochrane review has determined that patients with Stage II and III disease benefit from a six- to 24-month course of prednisolone but that treatment is not justified in those with Stage I disease.²² The typical starting dose is between 20 and 40 mg/d, which, in those that respond to therapy, can be gradually tapered to the minimally effective dose after two to three months. There is no consensus on the validity of treatment past two years²² and consideration of the significant morbidity associated with chronic steroid use is warranted. Inhaled corticosteroids appear to be ineffective in terms of both disease progression and symptomatic relief.²²

Cytotoxic agents, such as methotrexate and azathioprine, can be used as monotherapy or as steroid-sparing agents. They can be used in cases of refractory sarcoidosis or where corticosteroids are contraindicated and have been shown to induce remission in acute exacerbations of chronic sarcoidosis. The anti-malarial agents chloroquine and hydroxychloroquine have been reported to reduce disease activity in severe pulmonary sarcoidosis, although this is not without risk to the eye.²³ Ketoconazole has been suggested as a steroid-sparing agent in cases of refractory hypercalcaemic sarcoidosis.²⁴

As the cytokine TNF- α is intimately linked to the granuloma formation, a range of immunomodulators, such as infliximab,²⁵ have been trialled for the treatment of sarcoidosis.

THERAPY FOR OCULAR DISEASE

The visual prognosis in ocular sarcoidosis is variable, ranging from transient ocular irritation without impacting vision, through to sight-threatening choroiditis or optic nerve lesions.

Anterior uveitis is best treated aggressively with topical corticosteroids (prednisolone 1%, q1hr to q.i.d.) and topical cycloplegics (for example, homatropine 5%, scopolomine 0.25% or atropine 1%, b.i.d.), usually with good effect. Raised intraocular pressures are usually treated with topical aqueous suppressants (for example, timolol), though raised intraocular pressure in young patients with healthy optic discs is often left untreated as, most commonly, the ocular hypertension subsides concomitantly with resolution of the uveitis. Prostaglandin analogues, for example, Latanoprost (Xalatan) 0.005%, and miotics are contraindicated in the treatment of ocular hypertension associated with uveitis due to their pro-inflammatory action.

Significant intermediate or posterior uveitis rarely responds to simple topical therapy. Therefore, systemic corticosteroids (with or without oral non-steroidal anti-inflammatory agents) are indicated for treatment of optic neuritis and intermediate and posterior uveitis, especially if there is dense vitritis, poor vision or cystoid macular oedema.¹⁰ In some cases, injected periocular or sub-tenons steroid is used, particularly if there is mild and unilateral posterior uveitis. Where there is severe uveitis and either failure to respond to injected orbital steroids or a contraindication to systemic steroids, intravitreal injections of triamcinolone may be used to improve visual outcome.^{26,27} As with systemic sarcoidosis, immunosuppressive and anticytokine therapies have been suggested for refractory or sight-threatening disease,²⁸⁻³⁰ especially when associated with significant systemic disease.

Photocoagulation³¹ and vitrectomy³² may be used in cases of intermediate and posterior uveitis, where there is retinal neovascularisation and significant vitreous haemorrhage.

CONCLUSION

We present a case of sarcoidosis with Stage I pulmonary involvement, anterior and intermediate uveitis and constitutional symptoms. The unusual feature of the case is the bulky abdominal lymphadenopathy. Confounders in the clinical history include severe and rapid weight loss, abdominal pain (though peritoneal sarcoidosis has been described³³) and prior history of tuberculous exposure.

A diagnosis of sarcoidosis was reached following excisional biopsy of a superficial lymph node, following negative bronchoscopy and unremarkable haematological, biochemical and serological work-up.

Ocular involvement in sarcoidosis is common and may be the presenting feature of the disease. Prompt recognition and treatment may prevent visual loss and systemic complications.

ACKNOWLEDGEMENTS

We thank the members of the Department of Respiratory Medicine for their support and advice in preparing this manuscript.

REFERENCES

1. Baughman RP, Lower EE, du Bois RM. Sarcoidosis. *Lancet* 2003; 361: 1111-1118.
2. Haslet C, Chilvers ER, Corris PA. Respiratory disease. In: Haslet C, Chilvers ER, Boon NA, Colledge NR, eds. *Davidson's Principles and Practice of Medicine*, 19th ed. London: Churchill Livingstone, 2002. p 483-574.
3. Siltzbach LE, James DG, Neville E, Turiaf J, Battesti JP, Sharma OP, Hosoda Y, Mikami P, Odaka M. Course and prognosis of sarcoidosis around the world. *Am J Med* 1974; 57: 847-852.
4. Jones NP. Sarcoidosis and uveitis. *Ophthalmol Clin North Am* 2002; 15: 319-326.
5. Newman LS, Rose CS, Maier LA. Sarcoidosis. *N Engl J Med* 1997; 336: 1224-1234.
6. King TE. *Overview of sarcoidosis*, 2005. available online www.uptodate.com.
7. Verleden GM, du Bois RM, Bouros D, Drent M, Millar A, Muller-Quernheim J,

- Semenzato G, Johnson S, Sourvino G, Oliver D, Pietinalho A, Xaubet A. Genetic predisposition and pathogenetic mechanisms of interstitial lung diseases of unknown origin. *Eur Respir J* 2001; 32 Suppl: 17s–29s.
8. Nunes H, Soler P, Valeyre D. Pulmonary sarcoidosis. *Allergy* 2005; 60: 565–582.
 9. Hart LA, Conron M, du Bois RM. Sarcoidosis. *Int J Tuberc Lung Dis* 2001; 5: 791–806.
 10. Wu JJ, Schiff KR. Sarcoidosis. *Am Fam Physician* 2004; 70: 312–322.
 11. Statement on sarcoidosis. Joint Statement of the American Thoracic Society (ATS), the European Respiratory Society (ERS) and the World Association of Sarcoidosis and Other Granulomatous Disorders (WASOG) adopted by the ATS Board of Directors and by the ERS Executive Committee, February 1999. *Am J Respir Crit Care Med* 1999; 160: 736–755.
 12. Costabel U. Sarcoidosis: clinical update. *Eur Respir J* 2001; 32 Suppl: 56s–68s.
 13. Bonfioli AA, Orefice F. Sarcoidosis. *Semin Ophthalmol* 2005; 20: 177–182.
 14. Izumo M, Sekiya K, Sakai T, Tojima H. A male case of acute sarcoidosis with fever, polyarthralgia, erythema nodosum, and bilateral hilar lymphadenopathy: Lofgren's syndrome. *Nihon Kokyuki Gakkai Zasshi* 2005; 43: 761–765.
 15. Handbook of Ocular Disease Management: Jobson Publishing, 2001. available online www.revoptom.com.
 16. Bonfioli AA, Damico FM, Curi AL, Orefice F. Intermediate uveitis. *Semin Ophthalmol* 2005; 20: 147–154.
 17. Lobo A, Barton K, Minassian D, du Bois RM, Lightman S. Visual loss in sarcoid-related uveitis. *Clin Experiment Ophthalmol* 2003; 31: 310–316.
 18. Yanardag H, Pamuk ON. Lacrimal gland involvement in sarcoidosis. The clinical features of 9 patients. *Swiss Med Wkly* 2003; 133: 388–391.
 19. Shaikh ZA, Bakshi R, Greenberg SJ, Fine EJ, Shatla A, Lincoff NS. Orbital involvement as the initial manifestation of sarcoidosis: magnetic resonance imaging findings. *J Neuroimaging* 2000; 10: 180–183.
 20. Judson MA, Thompson BW, Rabin DL, Stimel J, Knatterud GL, Lackland DT, Rose C, Rand CS, Baughmann RP, Teirstein AS, Access Research group. The diagnostic pathway to sarcoidosis. *Chest* 2003; 123: 406–412.
 21. Heuser K, Kerty E. Neuro-ophthalmological findings in sarcoidosis. *Acta Ophthalmol Scand* 2004; 82: 723–729.
 22. Pietinalho A, Tukiainen P, Haahtela T, Persson T, Selroos O. Early treatment of stage II sarcoidosis improves 5-year pulmonary function. *Chest* 2002; 121: 24–31.
 23. Weisinger HS, Pesudovs K, Collin HB. Management of patients undergoing hydroxychloroquine (Plaquenil) therapy. *Clin Exp Optom* 2000; 83: 32–36.
 24. Conron M, Beynon HL. Ketoconazole for the treatment of refractory hypercalcemic sarcoidosis. *Sarcoidosis Vasc Diffuse Lung Dis* 2000; 17: 277–280.
 25. Thatayatikom A, Thatayatikom S, White AJ. Infliximab treatment for severe granulomatous disease in common variable immunodeficiency: a case report and review of the literature. *Ann Allergy Asthma Immunol* 2005; 95: 293–300.
 26. Yoshikawa K, Kotake S, Ichiishi A, Sasamoto Y, Kosaka S, Matsuda H. Posterior sub-Tenon injections of repository corticosteroids in uveitis patients with cystoid macular edema. *Jpn J Ophthalmol* 1995; 39: 71–76.
 27. Sonoda KH, Enaida H, Ueno A, Nakamura T, Kawano YI, Kubota T, Sakamoto T, Ishibashi T. Pars plana vitrectomy assisted by triamcinolone acetonide for refractory uveitis: a case series study. *Br J Ophthalmol* 2003; 87: 1010–1014.
 28. Benitez-del-Castillo JM, Martinez-de-la-Casa JM, Pato-Cour E, Mendez-Fernandez R, Lopez-Abad C, Matilla M, Garcia-Sanchez J. Long-term treatment of refractory posterior uveitis with anti-TNFalpha (infliximab). *Eye* 2005; 19: 841–845.
 29. Jones NP. Sarcoidosis. *Curr Opin Ophthalmol* 2002; 13: 393–396.
 30. Baughman RP, Lower EE, Bradley DA, Raymond LA, Kaufman A. Etanercept for refractory ocular sarcoidosis: results of a double-blind randomized trial. *Chest* 2005; 128: 1062–1047.
 31. Cheung CM, Durrani OM, Stavrou P. Peripapillary choroidal neovascularisation in sarcoidosis. *Ocul Immunol Inflamm* 2002; 10: 69–73.
 32. Kiryu J, Kita M, Tanabe T, Yamashiro K, Miyamoto N, Ieki Y. Pars plana vitrectomy for cystoid macular edema secondary to sarcoid uveitis. *Ophthalmology* 2001; 108: 1140–1144.
 33. Uthman IW, Bizri AR, Shabb NS, Khury MY, Khalifeh MJ. Peritoneal sarcoidosis: case report and review of the literature. *Semin Arthritis Rheum* 1999; 28: 351–354.

Corresponding author:
 Dr Harrison S Weisinger
 Department of Respiratory Medicine
 St Vincent's Hospital
 Fitzroy VIC 3065
 AUSTRALIA
 E-mail: weisinger@mac.com